

# Bone healing after dental extractions in irradiated patients: a pilot study on a novel technique for volume assessment of healing tooth sockets

Jimoh Olubanwo Agbaje · Reinhilde Jacobs ·  
Katleen Michiels · Mahmoud Abu-Ta'a ·  
Daniel van Steenberghe

Received: 18 July 2008 / Accepted: 9 October 2008 / Published online: 5 November 2008  
© Springer-Verlag 2008

**Abstract** The aim of this study was to evaluate longitudinally the bone-healing process by measuring volumetric changes of the extraction sockets in head and neck cancer patients undergoing radiotherapy after tooth extraction. A total group of 15 patients (nine males, six females) undergoing tooth extraction at the Department of Periodontology (University Hospital KULeuven) were enrolled after giving informed consent. In seven patients, teeth presenting a risk for complications and eventual radionecrosis were extracted prior to the radiotherapeutical procedure. Monitoring of bone healing was performed by evaluating the volumetric changes of the alveoli by cone beam CT scanning (CBCT) at extraction and after 3 and 6 months. In parallel, a similar longitudinal evaluation of extraction sites was done in a control group of eight patients. Within this pilot-study, a total of 15 healing extraction sockets were evaluated and followed up. There was a significant difference in volumetric fill up of extraction sockets in test group vs. control group at three ( $37.1 \pm 7.9\%$ ) vs. ( $54.6 \pm 4.0\%$ ) and 6 months ( $47.2 \pm 8.8\%$ ) vs. ( $70.0 \pm 7.3\%$ ), respectively. The present pilot study demonstrated the clinical usefulness of CBCT for evaluation of extraction socket healing. The study objectively demonstrates the delayed bone healing after tooth extraction in irradiated head and neck cancer patients. Consid-

ering the limitations of this pilot study, a potential effect of radiotherapy on further jaw bone healing after pre-therapeutic tooth extractions should be further explored.

**Keywords** Radiotherapy ·  
CBCT (cone beam computed tomography) ·  
Bone regeneration · Jaw bone · Tooth extraction ·  
Socket healing · Bone volume

## Introduction

Osteonecrosis is a growing problem in oral health care. Patients receiving radiotherapy are at high risk to have an impaired bone healing following surgical interventions. The same happens after the delivery, especially intravenously of bisphosphonates, a drug commonly prescribed to treat bone disorders characterised by increased bone resorption, such as Paget's disease, osteoporosis, hypercalcaemia, multiple myeloma and bony metastases [13–15, 22, 23].

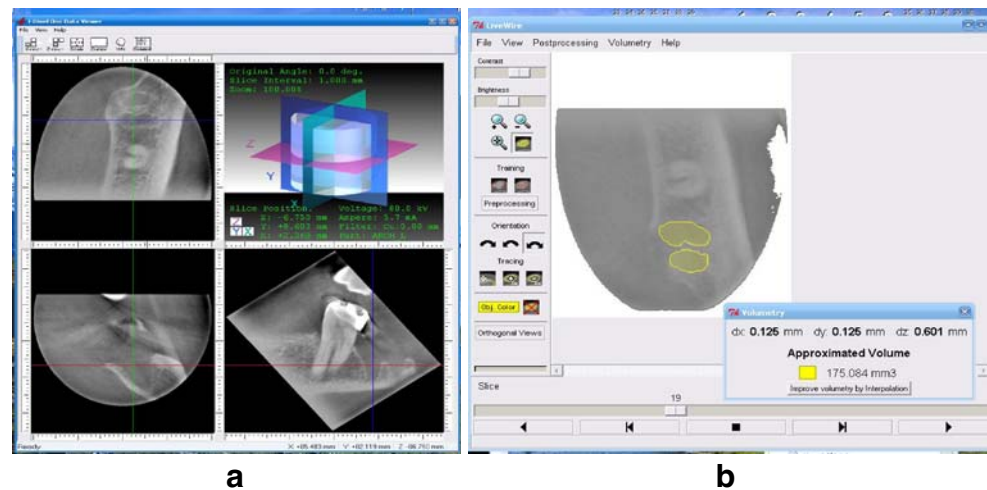
Healing of extraction socket has been extensively reported in the literature [3, 4, 12, 13, 18, 25]. Nevertheless, standardized procedures to compare healing under different circumstances, such as after radiotherapy in the head and neck regions remain scarce. Such comparative studies are much needed to evaluate the outcome of various treatment strategies to favour the healing process. Volumetric follow-up of bone fill during healing of an extraction socket has not been documented in the literature. Recently, Agbaje et al. [1] described a method to measure objectively volume of extraction socket from cone beam CT images of the jaws. This method could be applied to describe changes in volume of extraction socket during the healing process.

The aim of the present study was to validate clinically the volumetric assessment method by comparing healing in

J. O. Agbaje · R. Jacobs (✉)  
Oral Imaging Center, Faculty of Medicine, KU Leuven,  
Kapucijnenvoer 7,  
3000 Leuven, Belgium  
e-mail: Reinhilde.Jacobs@uz.kuleuven.be

K. Michiels · M. Abu-Ta'a · D. van Steenberghe  
Department of Periodontology, Faculty of Medicine,  
Katholieke Universiteit Leuven,  
Leuven, Belgium

**Fig. 1** **a** Screenshot from the AccuTomo I-Dixel software illustrating the three orthographic multi-planar reformatting (axial, coronal and sagittal) views. A high-resolution image like this shows the tooth sockets with a proper definition. **b** Screenshot from the LiveWire analysis software illustrating the segmentation process for volume quantification



radiotherapeutically treated head and neck cancer patients with a healthy subject group.

## Material and methods

### Materials

The test group consisted of 15 patients (mean age 60.9 years, age range 42–75 years; nine male, six female), consulting the Department Of Periodontology (University Hospital Leuven) related to periodontal breakdown and prognostically lost teeth including seven patients (five males, two females) with diagnosed oral or laryngeal cancer who were receiving an intense periodontal disinfection treatment, including extraction of tooth before the planned radiotherapy. Radiotherapy protocol involves fractionated irradiation with external photon beams to the target tissue, in this case, the head and neck region. The fractionation scheme can be 20×2 Gy (one fraction per day), 4×1.6 Gy (two fractions/day), 16×1.6 Gy (two fractions/day) given 72 Gy in total (46.4 Gy on the tumour and glands, and 25.6 Gy boost dose on tumour).

Another eight patients (four males, four females) who underwent a tooth extraction without diagnosis of oral or laryngeal malignant lesions, or history of radiotherapy served as a control group. Patients taking medication that influences bone healing (e.g. corticosteroids, bisphosphonates) were excluded. Informed consent was obtained from all these patients.

The clinical protocol consisted of cone beam CT examinations immediately after tooth extraction and at 3 and 6 months. Extraction sockets were scanned using a low dose but high resolution cone beam computed tomography (CBCT; AccuTomo®, Morita, Japan) to evaluate the healing process. Cone beam CT scan was

made at 4.0–5.7 mA and 80 kV, FOV of 40×30 mm diameter with a single 360° rotation and a total scan time of 17 s. This corresponds to a 20-μSv radiation dose.

### Methods

For all patients, the cone beam images were exported for volumetric measurements using the semi-automated analysis software known as LiveWire® (Institute of Computing, State University of Campinas, Brazil). The software allowed segmenting the tooth socket on consecutive 2D slices. After segmentation, the software computed the total

**Table 1** Volumetric change in a healing socket over a period of 3 months

No	Initial extraction socket volume (mm <sup>3</sup> )	Healing volume at 3 months (mm <sup>3</sup> )	Difference in socket volume (mm <sup>3</sup> )	% volume change
<b>Test group</b>				
1	125.19	78.25	46.94	37.50
2	207.68	160.00	47.68	22.96
3	153.37	98.96	54.41	35.48
4	200.13	107.75	92.38	46.20
5	182.58	98.50	84.08	46.05
6	110.64	70.14	40.50	36.61
7	123.42	80.73	42.69	34.59
<b>Control group</b>				
8	105.68	40.79	64.89	61.40
9	175.08	90.42	84.66	48.36
10	325.23	147.5	177.73	54.65
11	107.25	47.97	59.28	55.30
12	168.89	75.50	93.39	55.20
13	98.75	42.25	56.50	57.95
14	366.31	172.05	194.26	53.03
15	103.32	50.62	52.70	51.00

**Table 2** Volumetric change in a healing socket over a period of 6 months

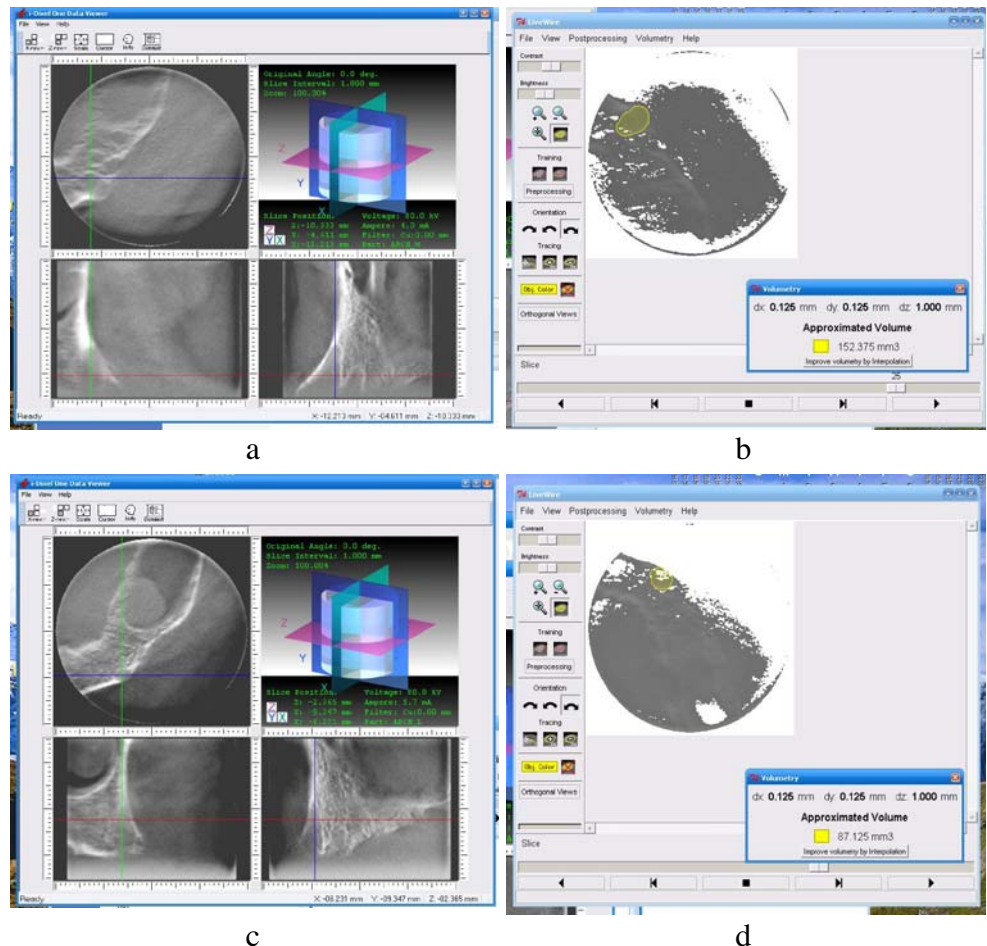
No	Initial extraction socket volume (mm <sup>3</sup> )	Healing volume at 6 months (mm <sup>3</sup> )	Difference in socket volume (mm <sup>3</sup> )	% Volume change
<b>Test group</b>				
1	125.19	64.69	60.50	48.33
2	207.68	146.35	61.33	29.53
3	153.37	87.12	66.25	43.20
4	200.13	95.75	104.38	52.16
5	182.57	82.72	99.86	54.67
6	110.64	50.26	60.38	54.57
7	123.42	64.25	59.17	47.94
<b>Control group</b>				
8	105.68	22.62	83.06	78.59
9	175.08	69.29	105.79	60.42
10	325.23	94.90	230.33	70.82
11	107.25	35.97	71.28	66.50
12	168.89	50.25	118.64	70.24
13	98.75	20.45	78.30	79.90
14	366.31	100.50	265.81	72.60
15	103.32	40.72	62.60	60.60

volume of the stack of segmented 2D slices. This corresponded to the socket volume. The DICOM format is not directly readable by the LiveWire software. Thus, the dataset was first converted to the SCN file format by Converter software dicom2scn. Dicom2scn converts sequences of 2D Dicom image files to the SCN volume format. Dicom2scn gets only the image data, its sizes along *x*, *y*, *z* and sizes of the voxel: *dx*, *dy* and *dz*. It skips name of patient and other information related to the examination but it does not change the image data. The SCN file was then imported into LiveWire.

The presence of soft tissue made the determination of socket edge less distinct. To overcome this problem, AccuTomo I-Dixel software<sup>®</sup> was used to show the socket view at each level of segmentation from radicular to coronal part of extraction socket. This was used as a guide during segmentation.

The extraction socket volume at month zero was considered as the baseline volume. The volume at months 3 and 6 was the socket volume remaining after bone deposition. The difference between months 0, 3 and 6 was considered as the socket filling over this period of

**Fig. 2** The axial images obtain on Cone beam CT. **a** Image obtains on CBCT after extraction and **c** 3 months after extraction, a marked reduction in volume of extraction socket can be observed. **b** and **d** Show the segmentation and volume quantification of a healing socket in **a** and **c**



time, reflecting a measure of the socket-healing process (Fig. 1a and b).

## Results

The limited sample in this pilot study did not allow inferential statistics, only descriptive data are provided.

For the extraction sockets at 3 months (Table 1) in test group the percentage volumetric changes range from 22.9–46.2% (mean  $37.1 \pm 7.9\%$ ) compared with 48.36–61.4% (mean  $54.6 \pm 4.0\%$ ) for the control group. Table 2 shows the volume change after a 6-month period. The percentage volumetric changes for test group range from 29.53–54.67% (mean  $47.2 \pm 8.8\%$ ) compared with 60.4–79.9% (mean  $70.0 \pm 7.29\%$ ) for the control group (Fig. 2).

## Discussion

The speed and quality of wound healing is governed by several factors like deficiency states, medication, presence or absence of disease, radiation and infection to mention a few [6, 8, 14, 17, 27]. There are also individual differences such as age, oral hygiene regimen, nutrition [2, 9, 20].

It has been known for a long time that ionizing irradiation among other factors can delay skin and bone wound healing and that the healing process is closely related to the radiation doses [20, 21, 26].

In the present study, differences in the rate of bone healing were investigated by comparing control with test group (head and neck cancer patients undergoing radiotherapy). During the healing process, bone is deposited and remodeling takes place causing a reduction in volume of the extraction socket. The reduction observed in bone volume during the 6-month study period agrees to the previous finding by Schropp et al. [25] who noted that large amount of mineralised tissue formed in the socket within the first 6 months.

The diminution in extraction socket volume corresponds to the amount of bone deposition during the healing process [7, 10, 19]. The rate of extraction socket healing can therefore be assessed by this decrease in volume of the extraction socket over a period of time. From our volumetric measurements we observed less reduction in volume of the extraction socket in test group as compared to the control. This agrees with studies by Ran and Shi et al, [20, 26] who noted decrease in wound healing on irradiated experimental animal and subject respectively.

This study has been able to show that bone healing can be assessed volumetrically using cone beam CT. Indeed, the cone beam CT appeared to provide high-resolution images which allow to discriminate anatomical landmarks in the

maxillo-facial area like the periodontal ligament, the trabecular pattern of bone, etc [11]. The use of segmentation software such as Livewire<sup>®</sup> reduces inter-observer variability and makes volume estimation from CBCT images efficient and accurate [5].

This pilot study also shows that the healing process is slower in patient undergoing radiotherapy when compared to the control group and that the healing process in these two groups can be quantified over time [7, 10, 19].

CBCT has a low-radiation dose [11, 16, 24, 28], while the image data set allows reliable and accurate volumetric assessment [1]. It provides a good research tool for monitoring bone healing and it may be interesting for planning surgery or implant placement in general.

## Conclusions

This pilot study confirms the clinical applicability of bone volumetric assessment using CBCT. Potentially, it may show a delayed or an impaired wound healing.

**Source of Funding** No external funding, apart from the support of the authors' institution, was available for this study.

**Conflict of Interest** No conflict of interest.

## References

1. Agbaje JO, Jacobs R, Maes F, Michiels K, van SD (2007) Volumetric analysis of extraction sockets using cone beam computed tomography: a pilot study on ex vivo jaw bone. *J Clin Periodontol* 34(11):985–990
2. Ai G, Su Y, Yan G, Wang M, Liu X, Xu H, Cheng T (2002) The experimental study of bone marrow mesenchymal stem cells on the repair of skin wound combined with local radiation injury. *Zhonghua Yi Xue Za Zhi* 82(23):1632–1636
3. Araujo MG, Sukekava F, Wennstrom JL, Lindhe J (2006) Tissue modeling following implant placement in fresh extraction sockets. *Clin Oral Implants Res* 17(6):615–624
4. Araujo MG, Wennstrom JL, Lindhe J (2006) Modeling of the buccal and lingual bone walls of fresh extraction sites following implant installation. *Clin Oral Implants Res* 17(6):606–614
5. Barrett WA, Mortensen EN (1997) Interactive live-wire boundary extraction. *Med Image Anal* 1(4):331–341
6. Bischof M, Nedir R, Szmukler-Moncler S, Bernard JP, Samson J (2004) Implant stability measurement of delayed and immediately loaded implants during healing. *Clin Oral Implants Res* 15(5):529–539
7. Butler JR, Rajnay ZW, Vernino AR, Parker D (1998) Volumetric changes following barrier regeneration procedures for the surgical management of grade II molar furcation defects in baboons: II. Bone, cementum, epithelium, and connective tissue. *Int J Periodontics Restorative Dent* 18(1):58–69

8. Colombier ML, Lesclous P, Tulasne JF (2005) Bone graft healing. *Rev Stomatol Chir Maxillofac* 106(3):157–165
9. Cromack DT, Porras-Reyes B, Purdy JA, Pierce GF, Mustoe TA (1993) Acceleration of tissue repair by transforming growth factor beta 1: identification of in vivo mechanism of action with radiotherapy-induced specific healing deficits. *Surgery* 113(1):36–42
10. Elsubeihi ES, Heersche JN (2004) Quantitative assessment of post-extraction healing and alveolar ridge remodelling of the mandible in female rats. *Arch Oral Biol* 49(5):401–412
11. Guerrero ME, Jacobs R, Loubele M, Schutyser F, Suetens P, van Steenberghe D (2006) State-of-the-art on cone beam CT imaging for preoperative planning of implant placement. *Clin Oral Investig* 10(1):1–7
12. Guglielmotti MB, Ubios AM, Cabrini RL (1985) Alveolar wound healing alteration under uranyl nitrate intoxication. *J Oral Pathol* 14(7):565–572
13. Guglielmotti MB, Ubios AM, Cabrini RL (1986) Alveolar wound healing after X-irradiation: a histologic, radiographic, and histometric study. *J Oral Maxillofac Surg* 44(12):972–976
14. Kalfas IH (2001) Principles of bone healing. *Neurosurg Focus* 10(4):E1
15. Kimmel DB (2007) Mechanism of action, pharmacokinetic and pharmacodynamic profile, and clinical applications of nitrogen-containing bisphosphonates. *J Dent Res* 86(11):1022–1033
16. Lascala CA, Panella J, Marques MM (2004) Analysis of the accuracy of linear measurements obtained by cone beam computed tomography (CBCT-NewTom). *Dentomaxillofac Radiol* 33(5):291–294
17. Lindaman LM (2001) Bone healing in children. *Clin Podiatr Med Surg* 18(1):97–108
18. Matin K, Nakamura H, Irie K, Ozawa H, Ejiri S (2001) Impact of recombinant human bone morphogenetic protein-2 on residual ridge resorption after tooth extraction: an experimental study in the rat. *Int J Oral Maxillofac Implants* 16(3):400–411
19. Rajnay ZW, Butler JR, Vernino AR, Parker DE (1997) Volumetric changes following barrier regeneration procedures for the surgical management of grade II molar furcation defects in baboons: I. Overall defect fill. *Int J Periodontics Restorative Dent* 17(4):378–391
20. Ran X, Cheng T, Lin Y, Qu J, Liu D, Ai G, Yan G, Wang W, Xu R (2003) Dose–effect relationships in total body irradiation on the healing of cutaneous wounds. *Chin Med J (Engl)* 116(6):878–882
21. Ran X, Cheng T, Shi C, Xu H, Qu J, Yan G, Su Y, Wang W, Xu R (2004) The effects of total-body irradiation on the survival and skin wound healing of rats with combined radiation-wound injury. *J Trauma* 57(5):1087–1093
22. Roelofs AJ, Thompson K, Gordon S, Rogers MJ (2006) Molecular mechanisms of action of bisphosphonates: current status. *Clin Cancer Res* 12(20 Pt 2):6222s–6230s
23. Russell RG (2007) Bisphosphonates: mode of action and pharmacology. *Pediatrics* 119(Suppl 2):S150–62
24. Scarfe WC, Farman AG, Sukovic P (2006) Clinical applications of cone-beam computed tomography in dental practice. *J Can Dent Assoc* 72(1):75–80
25. Schropp L, Wenzel A, Kostopoulos L, Karring T (2003) Bone healing and soft tissue contour changes following single-tooth extraction: a clinical and radiographic 12-month prospective study. *Int J Periodontics Restorative Dent* 23(4):313–323
26. Shi CM, Su YP, Cheng TM (2006) Recent advances in the pathological basis and experimental management of impaired wound healing due to total-body irradiation. *Med Sci Monit* 12(1):RA1–RA4
27. Song SJ, Pagel CN, Campbell TM, Pike RN, Mackie EJ (2005) The role of protease-activated receptor-1 in bone healing. *Am J Pathol* 166(3):857–868
28. Ziegler CM, Woertche R, Brief J, Hassfeld S (2002) Clinical indications for digital volume tomography in oral and maxillofacial surgery. *Dentomaxillofac Radiol* 31(2):126–130