



Research article

The mental foramen, anatomical parameters through a radiographic approach to aid in dental implantology: A retrospective analysis in a sample of a Palestinian population

Mahmoud F. Abu-Ta'a, Kamal J. Qubain, Khaled R. Beshtawi*

Department of Dental Sciences, Faculty of Graduate Studies, Arab American University, Palestine



ARTICLE INFO

Keywords:

Mental foramen
CBCT
Panorama
CBCT panorama
Profile

ABSTRACT

Purpose: This study aims at analyzing the mental foramen (MF) structure, dimension, position, and emergence profiles among a sample of a Palestinian population.

Methods: 212 mental foramina (106 patients) were analyzed on two panoramic views (CBCT reformatted (CRP) & conventional (CP)) and CBCT coronal views. The visibility score, position, size, presence of loop & supplementary foramina, distances coronal and apical to the foramen, and the emergence profiles of the mental canals with associated course angles were all noted.

Results: No statistically significant relationship was found between the type of panoramic radiographic view used (i.e., CP & CRP) and the resultant visibility level and position of MF. The majority of the MF showed an intermediate visibility score on both CP & CRP. The highest percentage of MF's position was under the 2nd mandibular premolar. The emergence profile was shown to be, in most, superior (S) in 47.6% of the sample and posterosuperior (PS) in 28.3%. The MF mean height and width were 4.08 mm & 4.11 mm, respectively. The coronal and axial angles averages were 46.25° and 91.49°, respectively. The distance superior and inferior to the MF showed averages of 12.39 mm and 13.52 mm, respectively. 28.3% of the sample presented with a mental loop, with a mesial extension average of 2 mm.

Conclusion: On both panoramic views (CBCT & conventional), the majority of the mental foramina displayed an intermediate visibility level, with no significant difference between the two techniques. The MF was found mostly under the second premolar. The majority of the examined mental canals had a superior emergence profile.

1. Introduction

The mental foramina (MF) are the terminal apertures of the mental canals that open on the mandibular buccal surfaces, where the neurovascular bundles of the inferior mandibular canal exit [1,2]. The mental canal, which develops inside the mandibular body, extends in several directions before terminating at the MF [1,2]. The emergence profile of the mental canal might adopt different directions including superior, posterosuperior, labial, anterior, and posterior [3,4]. The mental foramen's location in both horizontal and vertical planes can vary, along with their size and shape, which all have been related to the specific race and gender [3]. Thus, the pre-operative identification of the foramen is essential before many dental operations [5].

* Corresponding author.

E-mail addresses: mahmoud.abutaa@aaup.edu (M.F. Abu-Ta'a), Khaled.beshtawi@aaup.edu (K.R. Beshtawi).

Accessory mental foramen can be also found during 3D volume examinations [6]. Those were defined as buccal foramen with continuity to the mandibular canal whereas the ones without continuity with the mandibular canal were considered nutrient foramina [7].

Before the neurovascular bundles exit through the mental foramen, they may extend anteriorly in relation to the MF and then loop back before terminating at the MF, when such an anatomical finding exists, this is defined as a mental loop [8].

Although panoramic radiography is a very common radiograph prescribed in daily practice [9], cone-beam computed tomography (CBCT) has become a very popular radiographic modality that has revolutionized dental imaging practice [6]. It is now commonly utilized by many dental professions, including endodontics, implantology, and maxillofacial surgery [6]. One of the primary benefits is the generation of cross-sectional images of the anatomical landmarks, which exposes the patient to reduced radiation levels than computed tomography (CT scans) [10].

The presence of loop and/or accessory aperture, size, location, and direction of mental foramen are all characteristics that are vital to identify prior to dental implant therapy. Since these characteristics can be population-specific, this paper analyses them in a sample of Palestinian patients.

2. Material and methods

This study was a retrospective, cross-sectional, and radiographic study. The radiographic records of patients who attended the medical centre at Arab American University (Ramallah, Palestine) for general dental treatments between January 2018 and July 2022 were retrieved. The study was commenced after obtaining ethical clearance from the Palestinian health research council number: PHRC/HC/1088/22 and informed consent from the patients. The inclusion criteria included patients over 18 years old with no apparent jaw bone pathology in the region of interest, and patients who had both panoramic and CBCT volumes (taken at a maximum period of 6 months apart from each other). Cases where complete loss of teeth in the premolar-molar area where the 1st, 2nd premolars and 1st molar are missing, were excluded. Additionally, low-quality radiographs with apparent distortion or errors were also excluded. The panoramic radiographs were exposed using Sirona® XG5® (Dentsply Sirona®, Bensheim, Germany) where the CBCT volumes were acquired using the i-CAT™ FLX 17 (DEXIS™ Pennsylvania, USA) with exposure parameters: 64–73 kVp, 112 mAs and 120 kVp, 5 mA, 4.8s- 26.9 s, respectively. The radiographs were analyzed by two examiners (i.e., the principal investigator and a maxillofacial radiologist) using the panoramic software Sidexis® 4 (Dentsply® Sirona®, Bensheim, Germany) and the OnDemand® 3D Software (CyberMed®, Seoul, South Korea) for the CBCT volumes. The analysis was carried out and repeated completely (2 weeks after the primary analysis) by the principal investigator and partially and independently by the second examiner. Each examiner was trained independently before commencing the analysis to calibrate with the proposed methodology. The radiographs were analyzed on a desktop-grade monitor. The age and gender of patients were also recorded.

The visibility scores (VS) and the location (L) of the mental foramina were analyzed only on conventional & CBCT reformatted panoramic views. The visibility scores of the MF were determined as follows: 1 = poorly/not visible (i.e., none or less than one-quarter of the MF's borders are visible), 2 = intermediate visibility (i.e., at least half of the MF's borders are well defined), and 3 = excellent visibility (i.e., at least three-quarters of the MF's borders are well defined), (Fig. 1A–C). When radiographically identified (score 2&3) on both panoramic views, the MF's location (L) was recorded under these periapical/interradicular sites i.e., 1st mandibular premolar, 2nd mandibular premolar, between 1st and 2nd premolars, and between 2nd premolar and first molar. Regarding the CBCT reformatted panoramic view, the arch was reconstructed using the "Auto-arch" function in the software and at the level of mandibular teeth roots' mid-height (22 mm slice thickness). The presence of supplementary mental foramen (SMF) on CBCT axial & 3D model views was also checked. The existence of a mental loop (ML) on panoramic views (conventional & CBCT reformatted) was also noted. Confirmation of the mental loop on the corresponding axial views was done and if present, the mesial extension distance (MED) to a 90°-tangent line drawn crossing the external mesial aspect of the foramen was measured (Fig. 2A–D). The mental canal emergence profiles (EP) i.e., L = labially, S = superiorly, PS = posterosuperiorly, A = anteriorly, and AS = anterosuperiorly were analyzed on CBCT in two

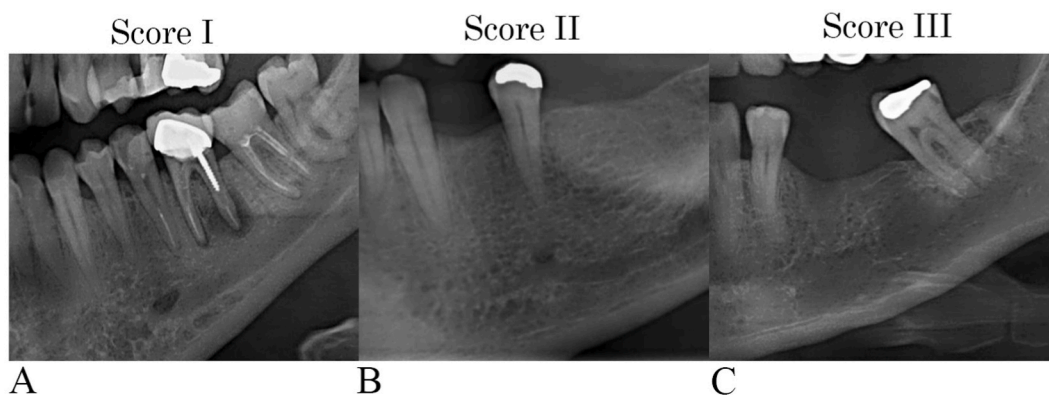


Fig. 1. The visibility scores of the mental foramen: (A) score I, (B) score II, (C) score III.

dimensions i.e., oblique coronal and axial views, (Fig. 3A–J). To standardize all the measurements (distances and angles), the MF were assessed on the selected slices coronally and axially where the MF had the maximum measured dimensions in all cuts in both views. The angulations of the course of the mental canal i.e., mid-point of the mental bundle were measured to the tangent of the buccal bone surface located distally on the axial (AA) and apical on the coronal (CA) planes, Fig. 4 (A&B) and Fig. 5 (C&D), respectively. The size of the mental foramen was also measured, i.e., maximum outermost mental height (MH) on coronal views (Fig. 5, A&B) and width (MW) on the axial views (Fig. 4, C&D). The distances measured on the coronal views from the uppermost and lower borders of the MF to the upper (DS) and lower border of the mandible (DI) were also recorded. Table 1 summarizes the variables analyzed in each radiographic view.

All data were analyzed using SPSS (IBM Corp. Released 2019. IBM SPSS Statistics for Windows, Version 26.0. Armonk, NY: IBM Corp). Normality tests to ensure the normal distribution of the data set were performed. Multiple statistical tests were used to check for a significant relationship between variables (e.g., visibility level & position of MF between CP vs. CRP, and the position of MF between the mandibular side assessed i.e., right vs. left) including Fisher's Exact and Chi-Square Tests. When the differences between measurements (e.g., MH, MW, DS, DI, CA, AA between different age groups, different genders, and different mandibular sides) have to be tested, the sample *t*-test, Mann–Whitney *U* test, Kruskal–Wallis test, and Wilcoxon signed-rank test were chosen. Tested variables were considered statistically significant at a 5% level (*p*-value). Intra- and interobserver reliability was checked using the intraclass correlation coefficient (ICC) where values between 0.75 and 0.9 indicate good reliability, and values greater than 0.90 indicate excellent reliability.

3. Results

Two hundred and twelve records were analyzed (106 patients, right and left sides) with different age and gender groups (Table 2). No statistically significant relationship was found between the type of radiographic view used (i.e., CP & CRP) and the resultant observations obtained for visibility level and position (Table 3). The majority of the MF showed intermediate visibility scores observed in CP and CRP (58.5% & 67.9%, respectively). The highest percentage of MF's position was under the 2nd mandibular premolar followed by “between 1st and 2nd premolars”, “between 2nd premolar and first molar”, and under 1st premolar for both CRP & CP views (Table 3). Furthermore, no statistically significant relationship was found between the MF's side (i.e., right & left) and the position of MF on CP and CRP (Table 4).

The emergence profile (EP) was shown to be in most superior (S) in 47.6% of the sample, posterosuperior (PS) in 28.3%, anterosuperiorly (AS) in 12.7%, anteriorly (A) & labially (L) in 5.7% each. Only the patients with posterosuperior (PS) emergence profiles showed a loop extension compared to the other profiles (60 canals (100%), statistically significant *p*-value 0.000). The gender and the EP showed no statistically significant relationship (Table 5).

For the 212 mental canals studied, the mental height (MH) showed an average of 4.08 mm [1.71 (min.) - 6.8 mm (max.), SD = 0.98], the width (MW) showed an average of 4.11 mm [2.05 (min.) - 7.3 mm (max.), SD = 1]. The distance superior (DS) and inferior (DI)

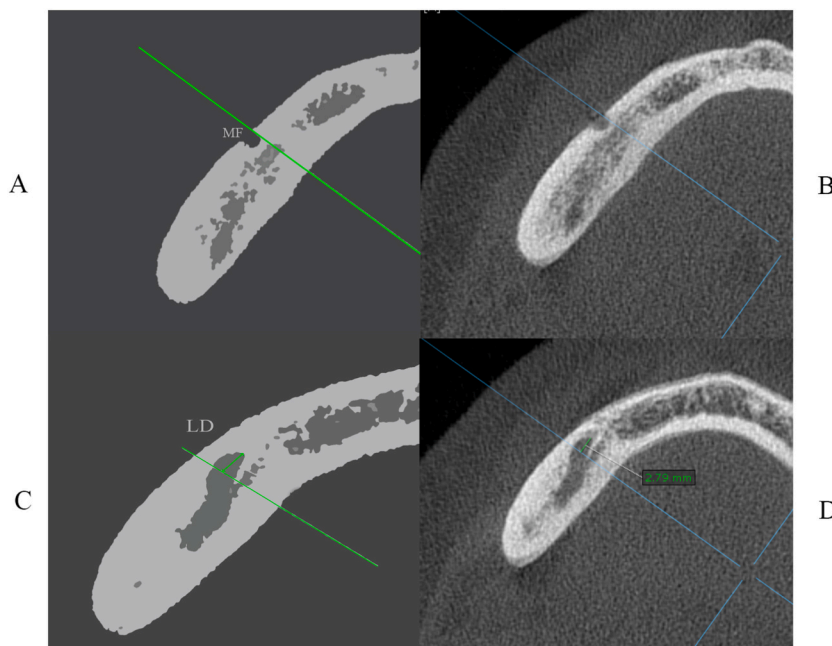


Fig. 2. Diagrams (A&C) and the corresponding CBCT axial views (B&D, respectively) of the MF showing the measurement of the mesial extension of the mental canal (mental loop).

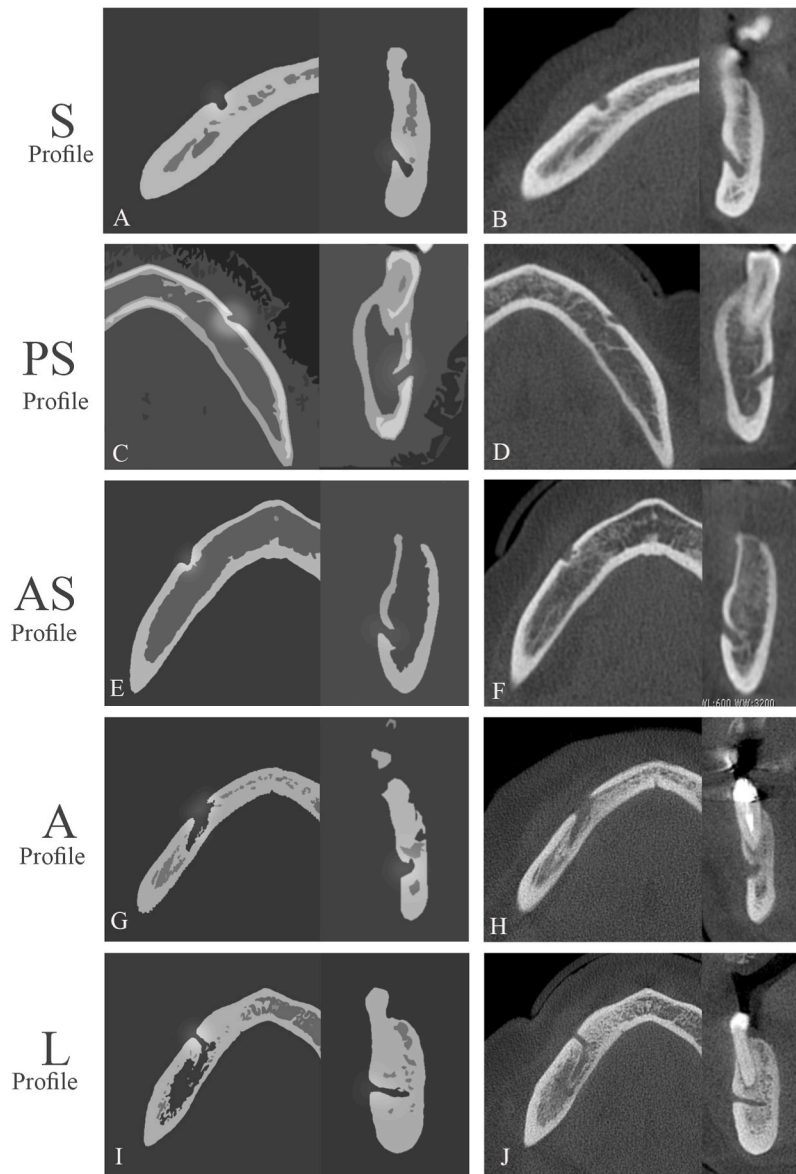


Fig. 3. Diagrams of the axial and coronal views and their corresponding CBCT axial views showing different MF's emergence profiles i.e., S = superiorly (A&B), PS = posterosuperiorly (C&D), AS = anterosuperiorly (E&F), A = anteriorly (G&H), and L = labially (I&J).

showed averages of 12.39 mm [2.6 mm (min.) - 22.4 mm (max.), SD = 3.26] and 13.52 mm [9.6 mm (min.) - 18.48 mm (max.), SD = 1.64], respectively. The coronal and axial angles averages were 46.25° [21.5° (min.) - 90.7° (max.), SD = 13.26] and 91.49° [29.9° (min.) - 137° (max.), SD = 23.92], respectively. The height (MH), and width (MW) of the mental foramen in addition to the distance superior (DS) & inferior (DI) showed statistically significant higher values for males compared to females (Table 5). The mean MF's height for males was 4.27 mm (SD \pm 0.98) compared to 3.68 mm (SD \pm 0.85) for females, where the width was 4.23 mm (SD \pm 1.04) and 3.89 mm (SD \pm 0.88), respectively. The mean distance superior (DS) and inferior (DI) showed 12.85 mm and 13.89 mm for males, respectively, and 11.45 mm and 12.78 for females.

28.3% of the sample revealed a mental loop (29.6% males vs. 25.7% females), with a mesial extension average of 2 mm [0.85 (min.) - 4.48 mm (max.), SD = 0.81]. Nonetheless, there was no statistically significant relationship between the presence of a loop and the patient's gender (Table 5).

Only five males showed supplementary foramen (SMF) with no statistically significant relationship with associated gender (Table 5). The mean maximum diameter of the SMF was 1.82 mm [1.02 mm - 2.36 mm].

The difference between MH, MF, DS, DI, CA, and AA on the right and left sides showed no statistical difference except in CA, where it was significantly higher on the left side (Table 6). Moreover, there was no statistically significant relationship between the mandibular sides (i.e., right & left) and the presence of SMF, ML, and EP. The comparison of the MH, MF, DS, DI, CA, and AA variables

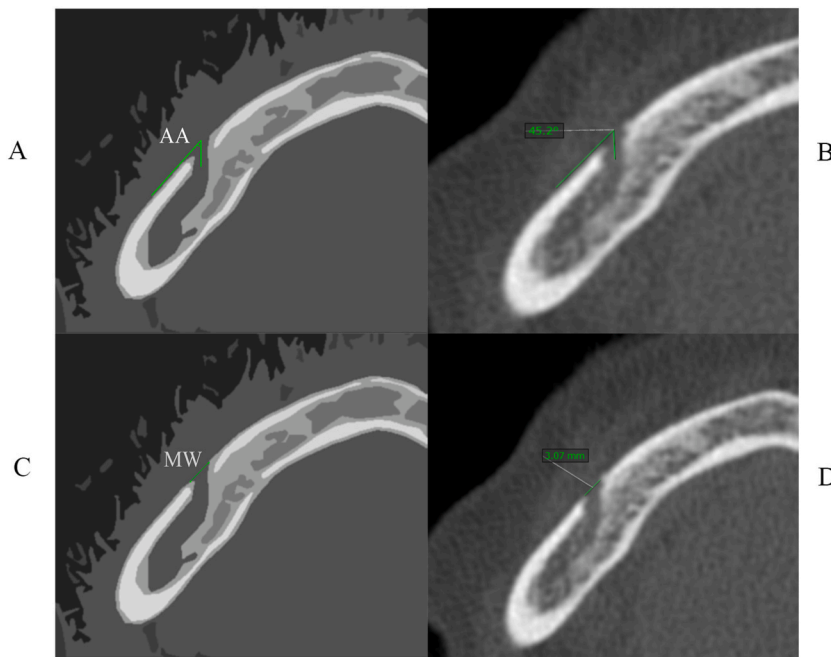


Fig. 4. Diagrams (A&C) and the corresponding CBCT axial views (B&D, respectively) of the MF showing the axial angle (AA) of the mental canal (A&B) and the measurement of the width (MW) of the MF's (C&D).

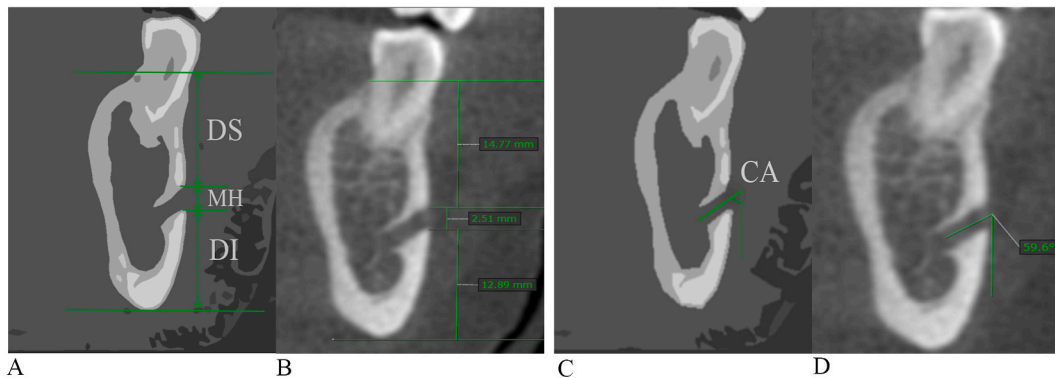


Fig. 5. Diagrams (A&C) and the corresponding CBCT coronal views (B&D, respectively) of the MF showing distance superior (DS) & inferior (DI) and height (MH) of the MF (A&B), and the coronal angle (CA) of the mental canal (C&D).

Table 1
The variables analyzed/measured on different radiographic views.

Radiographic view	Variables analyzed/measured
Panoramic views (Conventional & CBCT reformatted)	VS & L.
CBCT axial view	SMF, ML, MED, EP, AA, and MW.
CBCT coronal view	EP, CA, MH, DS, and DI.

among four different age groups elicited statistical significance in only DS, and CA (Table 7).

The average, minimum, maximum, and standard deviation values of the coronal and axial angles of the MF canal of different emergence profiles are summarized in Table 8. Obtuse angle (average value) was noted on the axial plane (AA) in the posterosuperior (PS) emergence profile, while the right angle (average value) was obtained in the superior (S) & labial (L) profiles, and the rest EP showed acute angles. The AS, PS, and S profiles presented with acute angles on the coronal view, while the labial (L) and anterior (A) profiles were on the higher end of the range of the obtuse angle. The interobserver ICC determined for the measure score 0.993 (95% CI: 0.991 to 0.994) while the intraobserver ICC for the measure was 0.998 (95% CI: 0.997 to 0.998).

Table 2
Demographic characteristics of patients.

	% (n)
Age	
20–29 years	5.7 (6)
30–39 years	13.2 (14)
40–49 years	34.0 (36)
≥50 years	47.1 (50)
Gender	
Male	67 (71)
Female	33 (35)

Table 3
Visibility level and position of mental foramen relationship between CBCT (CRP) & conventional panorama (CP).

	CP % (count)	CRP % (count)	Test-statistic	p-value
Visibility level			4.150 ‡	0.126
Not visible	22.2 (47)	17.9 (38)		
Intermediate	58.5 (124)	67.9 (144)		
Excellent visibility	19.3 (41)	14.2 (30)		
POSITION			0.185 ‡	0.980
1st mandibular premolar	3.1 (5)	2.9 (5)		
2nd mandibular premolar	49.1 (81)	48.9 (85)		
between 1st and 2nd premolars	33.9 (56)	35.6 (62)		
between 2nd premolar and first molar	13.9 (23)	12.6 (22)		

‡ Chi-Square Test. The position was determined where MF showed intermediate and excellent visibility scores).

Table 4
The relationship of the position of the mental foramen and the mandibular side analyzed on CRP & CP.

	Right % (count)	Left % (count)	Test-statistic	p-value
CBCT Panorama (CRP)			1.616 †	0.702
1st mandibular premolar	2.2 (2)	3.4 (3)		
2nd mandibular premolar	44.8 (39)	52.9 (46)		
between 1st and 2nd premolars	39.0 (34)	32.2 (28)		
between 2nd premolar and first molar	13.8 (12)	11.5 (10)		
Conventional Panorama (CP)			1.717 †	0.671
1st mandibular premolar	2.4 (2)	3.7 (3)		
2nd mandibular premolar	45.8 (38)	52.4 (43)		
between 1st and 2nd premolars	34.9 (29)	32.9 (27)		
between 2nd premolar and first molar	16.9 (14)	11.0 (9)		

† Fisher's Exact Test.

4. Discussion

The accurate demarcation of the mental canal structure is indispensable prior to various dental procedures. The ability of different radiographic modalities to accurately demarcate the mental foramen is variable [6]. In this study, the relationship between the used radiographic modality either conventional panorama or CBCT reformatted panorama and the level of visibility and the MF's position observed, has revealed no statistical significance. Nonetheless, the observers of this study had the impression that conventional panoramic radiographs presented better overall sharpness of the radiograph. Beshtawi et al. [6] found clinically tolerable differences in the vertical and horizontal positions of the mental foramen between the panoramic views (CP, CRP), and statistically and clinically significant differences compared to their counterparts in the coronal views (CORO). A study by Lupi et al. [11] examined the geometric distortion that might occur due to the flattening of 3D structures to 2D in panoramic reconstructions and found significant differences between the angle of the long axis of 2nd and 3rd mandibular molars recorded in CBCT panorama vs. 3D reconstruction. The visibility level of MF on panoramic radiographs was shown to be influenced by the age of the patient, shape and size, and the exit angle [12]. In a study by Ngeow et al. [13], they found that as patients advance in age, the visibility level of MF on panoramic radiographs decreases.

Table 5

A) The height (MH) & width (MW) of MF, distance superior (DS) & inferior (DI), angles coronal (CA) & axial (AA) for males compared to females. B) The relationship of the presence of supplementary MF, mental loop, and emergence profile and gender.

(A)	Male mean ± standard deviation	Female mean ± standard deviation	Test-statistic	p-value
MH (in mm)	4.27 (±0.98)	3.68 (±0.85)	4.301 †	0.000**
MW (in mm)	4.23 (±1.04)	3.89 (±0.88)	2.306 †	0.022**
DS (in mm)	12.85 (±3.33)	11.45 (±2.91)	3.013 †	0.003**
DI (in mm)	13.89 (±1.53)	12.78 (±1.60)	4.936 †	0.000**
CA (°)	45.96 (±14.12)	46.83 (±11.38)	-1.171 ‡	0.241
AA (°)	92.09 (±22.28)	90.26 (±27.06)	-0.343 ‡	0.732

(B)	Male % (count)	Female % (count)	Test-statistic	p-value
SUPPLEMENTARY MENTAL FORAMEN (SMF)			2.512 †	0.173
YES	3.5 (5)	0.0 (0)		
NO	96.5 (137)	100 (70)		
MENTAL LOOP (ML)			0.345 ‡	0.557
YES	29.6 (42)	25.7 (18)		
NO	70.4 (100)	74.3 (52)		
EMERGENCE PROFILE (EP)			4.498 ‡	0.343
PS	29.6 (42)	25.7 (18)		
AS	9.9 (14)	18.6 (13)		
A	5.6 (8)	5.7 (4)		
L	7.0 (10)	2.9 (2)		
S	47.9 (68)	47.1 (33)		

-† Independent sample t-test, ‡ Mann-Whitney U test, **statistically significant at (5% level).

-† Fisher's Exact Test, ‡ Chi-Square Test was used to calculate significant levels (P value). PS = posterosuperiorly, AS = anterosuperiorly, A = anteriorly, L = labially, and S = superiorly.

Table 6

A) The height (MH) & width (MW) of MF, distance superior (DS) & inferior (DI), angles coronal (CA) & axial (AA) differences between right vs. left mandibular sides. B) The relationship of the presence of supplementary MF, mental loop, and emergence profile and mandibular side.

(A)	Right mean (± standard deviation)	Left mean (± standard deviation)	Test-statistic	p-value
MH (in mm)	4.02 (±0.94)	4.14 (±1.01)	1.469 †	0.145
MW (in mm)	4.04 (±0.92)	4.19 (±1.08)	1.592 †	0.114
DS (in mm)	12.55 (±3.40)	12.23 (±3.12)	-1.434 ‡	0.152
DI (in mm)	13.57 (±1.60)	13.47 (±1.68)	0.706 †	0.482
CA (°)	45.10 (±13.09)	47.40 (±13.38)	-2.236 ‡	0.025**
AA (°)	92.16 (±24.41)	90.81 (±23.50)	-0.400 ‡	0.689

(B)	Right % (count)	Left % (count)	Test-statistic	p-value
SUPPLEMENTARY MENTAL FORAMEN (SMF)			0.204 †	1.000
YES	1.9 (2)	2.8 (3)		
NO	98.1 (104)	97.2 (103)		
MENTAL LOOP (ML)			1.488 ‡	0.223
YES	32.1 (34)	24.5 (26)		
NO	67.9 (72)	75.5 (80)		
EMERGENCE PROFILE (EP)			1.822 ‡	0.768
PS	32.1 (34)	24.5 (26)		
AS	11.3 (12)	14.2 (15)		
A	5.7 (6)	5.7 (6)		
L	4.7 (5)	6.6 (7)		
S	46.2 (49)	49.1 (52)		

-† Paired sample t-test, ‡ Wilcoxon signed-rank test. ** statistically significant at 5%.

-† Fisher's Exact Test, ‡ Chi-Square Test. PS = posterosuperiorly, AS = anterosuperiorly, A = anteriorly, L = labially, and S = superiorly.

4.1. MF position and size

The mental foramen position was under the 2nd premolar in the majority of the studied sample. Mohammad et al. [14] found that the commonest site of MF in a sample of a Palestinian population was between the 1st and 2nd premolar, followed by the position under the 2nd premolar. Meanwhile in Jordan [15], it was found that the most common site was in-between 1st and 2nd premolars. Haghanifar & Rokouei [16] reported the common site of the MF in a selected Iranian population to be between the 1st and 2nd

Table 7

The height (MH) & width (MW) of MF, distance superior (DS) & inferior (DI), angles coronal (CA) & axial (AA) differences in different age groups.

(A)	Group I mean (\pm standard deviation)	Group II mean (\pm standard deviation)	Group III mean (\pm standard deviation)	Group IV mean (\pm standard deviation)	Test-statistic	p-value
MH (in mm)	3.80 \pm 0.81	4.00 \pm 0.76	4.18 \pm 0.98	4.06 \pm 1.04	2.394 ‡	0.495
MW (in mm)	3.96 \pm 0.85	4.38 \pm 1.07	4.09 \pm 0.98	4.07 \pm 1.02	2.378 ‡	0.498
DS (in mm)	11.83 \pm 4.01	13.69 \pm 2.30	12.58 \pm 2.69	11.96 \pm 3.58	12.164 ‡	0.007**
DI in mm	13.38 \pm 1.94	13.93 \pm 1.43	13.38 \pm 1.79	13.53 \pm 1.54	2.199 ‡	0.532
CA (°)	50.71 \pm 19.35	41.35 \pm 7.83	45.13 \pm 13.68	47.89 \pm 13.01	8.316 ‡	0.040**
AA (°)	108.08 \pm 19.77	95.49 \pm 14.48	86.41 \pm 27.60	92.03 \pm 22.69	7.739 ‡	0.052

-‡ Kruskal-Wallis test. ** statistically difference (at 5%). Age groups: Group I (20–29 years), Group II (30–39 years), Group III (40–49 years), Group IV (\geq 50 years).

Table 8

Average (Avg.), minimum (Min.), maximum (Max.), and standard deviation (SD) of the coronal and axial angles of the MF canal of different emergence profiles.

Profile	Plane	Min.	Max.	SD	Avg.
L	Coronal (°)	47.4	90.7	12.4	75.1
	Axial (°)	79.7	102	8.0	90.4
A	Coronal (°)	42.3	88.3	17.7	64.2
	Axial (°)	29.9	91.6	17.3	50.5
AS	Coronal (°)	27.5	56.1	7.3	40.1
	Axial (°)	33.5	95	15.3	57.8
PS	Coronal (°)	21.5	63.4	9.1	40.3
	Axial (°)	97.1	137	10.9	118.3
S	Coronal (°)	21.6	81.5	9.3	45.9
	Axial (°)	48.5	113.3	9.7	89.6

premolars (47.2%) and under the 2nd premolar (46%). Fabian [4] found that 45% of the Tanzanian sample presented the mental foramen under the second premolar, followed by 35% in-between 2nd premolar and 1st molar, and 12% between the 1st premolar and 2nd premolar. The majority (64.3%) of a Korean sample [17] showed the MF under the 2nd premolar, followed by 26.8% between the 1st and 2nd premolar, and lastly under the 1st premolar (8.9%). A study in Switzerland [18] showed that the commonest site was between the 1st and 2nd premolar (56%) and under the 2nd premolar (35.7%).

Ahmed et al. [19] reported a significant difference between Saudi genders in terms of MF's mean height and width values (i.e., a height of 3.14 mm for males, 1.64 mm for females and a width of 3.57 mm for males and 1.19 mm for females). Von Arx et al. [18] reported a mean height of 3 mm and a mean width of 3.2 mm in a study in Switzerland. In the current analysis, the mental foramen displayed a size of 4.08 mm_(mean) in height and 4.11 mm_(mean) in width. MF's size (MH&MW) was found to be statistically different between the genders -but not between the right and left sides-, with the males showing larger MF dimensions than the females. Muinelo-Lorenzo et al. [20] indicated that factors including gender and jaw side (right and left) were found associated with the MF dimensions.

4.2. Supplementary mental foramen (SMF)

Supplementary mental foramen (SMF) is a miniature foramen found in the vicinity of the main mental foramen, which is vital to identify prior to various surgical procedures in that region [21]. In this study, SMF were detected 5 times, 2 of which were bilateral for the same patient. Some of them were found in anterior, posteroinferior, and in posterosuperior positions in relation to the main MF. The size of the SMF was found [21,22] to be submillimeter, our sample analysis showed a higher diameter average of 1.8 mm. The detection of supplementary foramen on panoramic radiographs is challenging [12,21,23,24], on the contrary, CBCT was found to be an effective tool to detect such anatomical variation [6,23]. In the current study, none of the observed SMF was detected on both panoramic views (conventional & CBCT reformatted) and only were detected on axial and 3D models.

4.3. Emergence profile (EP)

The emergence profile of the mental canal was found to be mostly in a superior direction (44%) in a Tanzanian sample [4], other mental canals were found to be posterosuperior, labially, mesially, and posteriorly in 40%, 10%, 3%, and 3% respectively. In a study sample in Switzerland [18], the mental canal direction was superior (in all the sample size) where 72.5% of the sample showed also a posterior course (posterosuperior). In a study in Spain [20], the superior direction was the most common emergence profile followed

by direct, posterior and anterior courses. These studies were in concur with our findings where 47.6% and 28% of the sample were superior and posterosuperior, respectively.

4.4. Mental loop

Failure to recognize the presence of mental loops and consequently accurately identify their dimensions would lead to serious consequences including -if jeopardized e.g., during implant placement-neurosensory disturbance of the chin and lower lip [25]. Vujanovic-Eskenazi et al. [26] found that 36.6% and 48.8% of the studied sample showed the mental loop on panoramic and CBCT volumes, respectively, and only 24.4% of the sample revealed the loop on both radiographic modalities. The mean length of the mental loop was 1.59 [0.4–4.0 mm] [26]. Eachempati et al. [25] found the mean CBCT length of the anterior loop to be 2.66 mm (± 0.84). Chen et al. [27] found that in a sample of Taiwanese participants, there was a significantly longer anterior loop compared to their American counterparts (7.61 ± 1.81 mm to 6.22 ± 1.68 mm, respectively). It was also reported in that the mesial loop distance was less than 2 mm in 44.5% of the sample while only 1.6% were more than 4 mm in Saudi Arabia [19].

In the current analysis, sixty mental canals (28.3%) were observed with a mesial extension. The length of these loops was ranging from 0.85 to 4.48 mm with an average of 2 mm. All of these loops were found only in the posterosuperior-directed canals.

4.5. Distance superior (DS) & inferior (DI) and angles (CA, AA)

In the current analysis, the distance superior (DS) and inferior (DI) showed averages of 12.39 mm and 13.52 mm, respectively. The coronal (CA) and axial angles (AA) averages in the current study were 46.25° [21.5° – 90.7°] and 91.49° [29.9° – 137°], respectively. Only the CA difference between the right and left sides was statistically significant. Although in this current analysis the CA & AA were not statistically significant between genders, Muinelo-Lorenzo et al. [12] found that males showed significantly higher MF “exit angle” than females. The comparison of the coronal angle (CA) between this study and the other studies should be done with caution as some consider the CA as the angle between the main course of the mental canal and the tangent of cortical bone located coronally [18,19] or apically [20] to the MF.

A study [28] evaluating the anatomical location of the MF in medical computed tomography (CT) showed an average superior distance of the MF to the alveolar crest of 14.2 mm [10.7 mm–20.5 mm]. Von Arx et al. [18] reported a mean distance of 12.6 mm [5.7 mm–19.6 mm] and 13.2 mm [9.7 mm–19.3 mm] from the MF to the alveolar crest and from the MF to the inferior mandibular cortex (IMC), respectively. The reported angle of the mental canal on the axial plane was 69.2° [39.3° – 127.8°] and on the coronal plane 46.8° [24.2° – 81.3°]. Ahmed et al. [19] reported a higher mean value in both distances of MF for males compared to females in Saudi Arabia i. e., MF to the alveolar crest: 14.21 mm (for males) & 13.48 mm (for females), and MF to IMC 13.58 mm (for males) and 12.06 mm for (females). The reported angle of the mental canal on the axial plane for males was 76.40° and for females was 77.65° [19]. The coronal angles of the mental canal for males were 46.67° and for females 42.38° [19]. Gender and age did not affect these angles [19]. Muinelo-Lorenzo et al. [20] reported a superior MF mean distance of 11.42 (± 3.34 mm), an inferior distance to the IMC of (13.55 \pm 1.06 mm), and a mental canal emerging angle of ($53.45 \pm 15.90^\circ$) in a studied Spanish sample. Kalender et al. [29] studied the MF in a Turkish population and reported a mean inferior distance (MF – IMC) of 12.6 mm (± 1.7), moreover, this distance was shown to be higher for males compared to females. The distance from the superior border of the mental foramen to the inferior border of the mandible was shown to differ significantly between genders in a study conducted by Sheikhi & Kheir [30]. Other studies [12,31] also showed that distances from the MF to the alveolar crest and inferior mandibular border were significantly higher for males.

4.6. Limitations

The perception of the visibility level of mental foramen borders may be influenced by the radiographic exposure parameters (and subsequently the resultant quality) and to some extent the examiner’s experience or personal judgment. Further research is required to determine the effect of these variables in the radiographic interpretation of the structure of the mental foramen.

5. Conclusion

Most of the mental foramina showed an intermediate visibility score on both panoramic views (CBCT & conventional), without a significant relationship between the used radiograph’s type and the visibility level. The position of the MF was in most under the 2nd premolar with no statistical significance between the right and left sides. The majority of the studied mental canals were in a superior emergence profile with no statistical difference between genders and the right and left sides. A considerable amount of the sample (28.3%) existed with mental loop, and only in 4 patients supplementary foramina were detected (with one existing bilaterally).

Author contribution statement

Mahmoud Abu-Ta'a: Conceived and designed the experiments; Analyzed and interpreted the data; Wrote the paper.

Kamal Qubain: Performed the experiments; Analyzed and interpreted the data; Contributed reagents, materials, analysis tools or data; Wrote the paper.

Khaled Beshtawi: Conceived and designed the experiments; Performed the experiments; Analyzed and interpreted the data; Wrote the paper.

Funding statement

This research did not receive any specific grant from funding agencies in the public, commercial, or not-for-profit sectors.

Data availability statement

Data included in article/supp. material/referenced in article.

Declaration of interest's statement

The authors declare no competing interests.

Acknowledgment

The authors would like to thank Dr Maryam Fasfous for her assistance in the statistical analysis, and Radiographer Mr Osama Ajaj for his assistance in the data collection.

References

- [1] J.L. Phillips, R.N. Weller, J.C. Kulild, The mental foramen: Part I. Size, orientation, and positional relationship to the mandibular second premolar, *J. Endod.* 16 (1990) 221–223, [https://doi.org/10.1016/S0099-2399\(06\)81674-2](https://doi.org/10.1016/S0099-2399(06)81674-2).
- [2] V. Gupta, P. Pitti, A. Sholapurkar, Panoramic radiographic study of mental foramen in selected dravidians of south Indian population: a hospital based study, *J. Clin. Exp. Dent.* 7 (2015) e451, <https://doi.org/10.4317/jced.52174.-e456>.
- [3] G. Juodzbalys, H.-L. Wang, G. Sabalys, Anatomy of mandibular vital structures. Part II: mandibular incisive canal, mental foramen and associated neurovascular bundles in relation with dental implantology, *J. Oral Maxillofac. Res.* 1 (2010), <https://doi.org/10.5037/JOMR.2010.1103>.
- [4] F.M. Fabian, Position, shape and direction of opening of the mental foramen in dry mandibles of Tanzanian adult black males, *Ital. J. Anat Embryol.* 112 (2007) 169–177.
- [5] G. Greenstein, D. Tarnow, The mental foramen and nerve: clinical and anatomical factors related to dental implant placement: a literature review, *J. Periodontol.* 77 (2006) 1933–1943, <https://doi.org/10.1902/JOP.2006.060197>.
- [6] K. Beshtawi, E. Qirresh, M. Parker, S. Shaik, Custom focal trough in Cone-beam computed tomography reformatted panoramic versus digital panoramic for mental foramen position to aid implant planning, *J. Clin. Imag. Sci.* 10 (2020), <https://doi.org/10.25259/JCIS.150.2019>.
- [7] M. Naitoh, Y. Hiraiwa, H. Aimiya, et al., Accessory mental foramen assessment using cone-beam computed tomography, *Oral Surg. Oral Med. Oral Pathol. Oral Radiol. Endod.* 107 (2009) 289–294, <https://doi.org/10.1016/J.TRIPLEO.2008.09.010>.
- [8] J.B. Bavitz, S.D. Harn, C.A. Hansen, M. Lang, An anatomical study of mental neurovascular bundle-implant relationships, *Int. J. Oral Maxillofac. Implants* 8 (1993) 563–567.
- [9] D.A. Tyndall, J.B. Price, S. Tetradis, et al., Position statement of the American Academy of Oral and Maxillofacial Radiology on selection criteria for the use of radiology in dental implantology with emphasis on cone beam computed tomography, *Oral Surg. Oral Med. Oral Pathol. Oral Radiol.* 113 (2012) 817–826, <https://doi.org/10.1016/j.oooo.2012.03.005>.
- [10] M.M. Bornstein, K. Horner, R. Jacobs, Use of cone beam computed tomography in implant dentistry: current concepts, indications and limitations for clinical practice and research, *Periodontol* 73 (2017) 51–72, 2000.
- [11] S.M. Lupi, P. Galinetto, M. Cislighi, et al., Geometric distortion of panoramic reconstruction in third molar tilting assessments: a comprehensive evaluation, *Dentomaxillofacial Radiol.* 47 (2018), <https://doi.org/10.1259/DMFR.20170467>.
- [12] J. Muínelo-Lorenzo, J.A. Suárez-Quintanilla, A. Fernández-Alonso, et al., Anatomical characteristics and visibility of mental foramen and accessory mental foramen: panoramic radiography vs. cone beam CT, *Med. Oral Patol. Oral Cir. Bucal* 20 (2015) e707, <https://doi.org/10.4317/MEDORAL.20585.-e714>.
- [13] W.C. Ngeow, D.D. Dionysius, H. Ishak, P. Nambiar, Effect of ageing towards location and visibility of mental foramen on panoramic radiographs, *Singapore Dent. J.* 31 (2010) 15–19, [https://doi.org/10.1016/S0377-5291\(12\)70004-4](https://doi.org/10.1016/S0377-5291(12)70004-4).
- [14] Z.K. Mohammad, R. Shadid, M. Kaadna, et al., Position of the mental foramen in a northern regional Palestinian population, *Int. J. Oral Craniofac. Sci.* 2 (2016) 57–64, <https://doi.org/10.17352/2455-4634.000020>.
- [15] T. Al-Khateeb, A. Al-Hadi Hamasha, K.T. Ababneh, Position of the mental foramen in a northern regional Jordanian population, *Surg. Radiol. Anat.* 29 (2007) 231–237, <https://doi.org/10.1007/S00276-007-0199-Z>.
- [16] S. Haghaniifar, M. Rokouei, Radiographic evaluation of the mental foramen in a selected Iranian population, *Indian J. Dent. Res.* 20 (2009) 150–152, <https://doi.org/10.4103/0970-9290.52886>.
- [17] I.S. Kim, S.G. Kim, Y.K. Kim, J.D. Kim, Position of the mental foramen in a Korean population: a clinical and radiographic study, *Implant Dent.* 15 (2006) 404–411, <https://doi.org/10.1097/01.ID.0000243319.66845.15>.
- [18] T. von Arx, M. Friedli, P. Sendi, et al., Location and dimensions of the mental foramen: a radiographic analysis by using cone-beam computed tomography, *J. Endod.* 39 (2013) 1522–1528, <https://doi.org/10.1016/J.JOEN.2013.07.033>.
- [19] A.A. Ahmed, R.M. Ahmed, A. Jamlah, G. Spagnuolo, Morphometric analysis of the mandibular canal, anterior loop, and mental foramen: a cone-beam computed tomography evaluation, *Int. J. Environ. Res. Publ. Health* 18 (3365 18) (2021) 3365, <https://doi.org/10.3390/IJERPH18073365>, 2021.
- [20] J. Muínelo-Lorenzo, A. Fernández-Alonso, E. Smyth-Chamosa, et al., Predictive factors of the dimensions and location of mental foramen using cone beam computed tomography, *PLoS One* 12 (2017), <https://doi.org/10.1371/JOURNAL.PONE.0179704>.
- [21] T.S.N. Imada, S.R. Fernandes Lmp da, B.S. Centurion, et al., Accessory mental foramina: prevalence, position and diameter assessed by cone-beam computed tomography and digital panoramic radiographs, *Clin. Oral Implants Res.* 25 (2012) e94, <https://doi.org/10.1111/CLR.12066.-e99>.
- [22] H. Toh, J. Kodama, M. Yanagisako, T. Ohmori, Anatomical study of the accessory mental foramen and the distribution of its nerve, *Okajimas Folia Anat. Jpn.* 69 (1992) 85–88, <https://doi.org/10.2535/OFAJ1936.69.2-3.85>.
- [23] K. Katakami, A. Mishima, K. Shiozaki, et al., Characteristics of accessory mental foramina observed on limited cone-beam computed tomography images, *J. Endod.* 34 (2008) 1441–1445, <https://doi.org/10.1016/J.JOEN.2008.08.033>.
- [24] F.S. Neves, M.C.C. Nascimento, M.L. Oliveira, et al., Comparative analysis of mandibular anatomical variations between panoramic radiography and cone beam computed tomography, *Oral Maxillofac. Surg.* 18 (2014) 419–424, <https://doi.org/10.1007/S10006-013-0428-Z>.
- [25] P. Eachempati, S. Kumbargere Nagraj, D.C.W. Chien, et al., Radiographic evaluation of the anterior loop of the mental nerve: comparison between orthopantomograph and cone-beam C T – a pilot study, *Res. J. Pharmaceut. Biol. Chem. Sci.* 8 (2017) 2044–2050.
- [26] A. Vujanovic-Eskenazi, J.M. Valero-James, M.A. Sánchez-Garcés, C. Gay-Escoda, A retrospective radiographic evaluation of the anterior loop of the mental nerve: comparison between panoramic radiography and cone beam computerized tomography, *Med. Oral Patol. Oral Cir. Bucal* 20 (2015) e239, <https://doi.org/10.4317/MEDORAL.20026>.

- [27] J.C.H. Chen, L.M. Lin, J.R. Geist, et al., A retrospective comparison of the location and diameter of the inferior alveolar canal at the mental foramen and length of the anterior loop between American and Taiwanese cohorts using CBCT, *Surg. Radiol. Anat.* 35 (2013) 11–18, <https://doi.org/10.1007/S00276-012-0986-Z>.
- [28] A. Haktanır, K. Ilgaz, N. Turhan-Haktanır, Evaluation of mental foramina in adult living crania with MDCT, *Surg. Radiol. Anat.* 32 (2010) 351–356, <https://doi.org/10.1007/S00276-009-0572-1>.
- [29] A. Kalender, K. Orhan, U. Aksoy, Evaluation of the mental foramen and accessory mental foramen in Turkish patients using cone-beam computed tomography images reconstructed from a volumetric rendering program, *Clin. Anat.* 25 (2012) 584–592, <https://doi.org/10.1002/CA.21277>.
- [30] M. Sheikhi, M.K. Kheir, CBCT assessment of mental foramen position relative to anatomical landmarks, *Int. J. Dent.* (2016) 1–4, <https://doi.org/10.1155/2016/5821048>, 2016.
- [31] A. Mohammad Aldayel, M. Almutairi, G. Ali Alsuliaman, et al., Mental foramen as an indicator of patient's gender, panoramic study in Qassim province, Saudi Arabia, *J. Dent. Health Oral Disord. Ther.* 13 (2022) 69–72, <https://doi.org/10.15406/jdhodt.2022.13.00575>.