



Review article

Clinical comparison between different surgical techniques used to manage advanced gingival recession (Miller's class III & IV)

Cezar Lahham^{*}, Mahmoud Abu Ta'a^{*}

Dental Science Department, Faculty of Graduate Studies, Arab American University, Palestine

ARTICLE INFO

Keywords:

Advanced gingival recession
Surgical techniques
Clinical outcomes
Clinical condition

ABSTRACT

Advanced gingival recession is considered a complex soft tissue problem, which is increased in severity with age, and has multiple etiological factors. Therefore, the treatment is very complicated with low predictability. However, in the last decade, many clinical trials have shown highly predictable results when managing advanced recession cases by surgical intervention.

The present review shows different surgical techniques with their clinical outcomes in order to choose the most suitable technique required by the clinical condition. Although there are relatively few studies, modified tunnel technique and coronal advanced flap (CAF) showed the highest percentage of root coverage (%RC) during the first year (up to 86%). These techniques are primarily indicated to manage advanced recession in the esthetic zone. Pedicle buccal fat pad (PBFP) also had a good percentage of root coverage when used in the maxillary posterior area, as it has a high blood supply with minimal risk for infection and necrosis. Free gingival graft (FGG) can be used in the mandibular anterior area, as it creates a band of keratinized tissue that can resist recession with a fair percentage of root coverage. However, color match and graft shrinkage are the main problems of this procedure.

1. Introduction

Gingival recession is considered one of the most common problems affecting the periodontium. About 50% of the population has at least 1 mm gingival recession [1], and 5–32% of adults have advanced gingival recession [2]. Recession is not only an esthetic problem, but can increase root sensitivity as well hindering optimal oral hygiene.

Recession can happen due to several factors, such as periodontal disease, aggressive tooth brushing, improper orthodontic treatment, a minimal amount of keratinized tissue...etc. [3] Therefore, the management of gingival recession depends primarily on its severity, extent and the etiological factor. Generally, simple cases (Miller's class I/II) can be managed with high predictability, up to 100% root coverage after the surgical intervention [4]. However, advanced recession cases (Miller's Class III and IV) are challengeable [5], with reduced predictability. Recently, many publications have showed high mean of root coverage with a high percentage of complete root coverage for advanced recession cases. This promoted Miller to publish a new article in 2018, to clarify the role of papilla width in raising the probability of success of the surgical procedure for advanced recession cases [6]. For this reason, a proper examination is the key for successful management.

Here, we review the literature on surgical techniques that are used to manage advanced recession. In addition to show their indications and clinical outcomes in order to make a proper decision when facing advanced recession cases.

2. Searching methods and data collection

Data & Sources: The data collection was performed by using PubMed, Cochrane, and Google Scholar databases. A Review was carried out on all published articles that were related to the topic up to December 1, 2021.

Study selection: The criteria for inclusion were: 1) articles addressing advanced gingival recession, miller's class III, miller's class IV, recession type 2, recession type 3, complex gingival recession, and dark triangles. 2) in vivo human studies 3) case reports 4) randomized control trials 5) systematic reviews & meta-analysis. The criteria for exclusion were: 1) animal studies 2) articles that do not focus on management and clinical outcomes.

3. Surgical techniques for treating Miller's class III/IV (advanced gingival recession)

3.1. Coronal advanced flap (CAF)

In 1995, CAF was introduced by Bernimoulin et al., and it is considered one of the most common surgical techniques used to treat gingival

^{*} Corresponding authors.

E-mail addresses: cezarlahham@hotmail.com (C. Lahham), mahmoud.abutaa@aaup.edu (M.A. Ta'a).

recession. It could be used alone for simple cases, but it is recommended to be used in combination with soft tissue graft (e.g., connective tissue graft, acellular dermal matrix, enamel matrix derivative, collagenous membrane, platelet-rich fibrin) to increase its predictability and long-term stability [7, 8].

CAF can be performed in one stage when there is a sufficient amount of keratinized gingiva and thick biotype. Whereas if the amount of keratinized gingiva or/and gingival thickness is/are compromised, the soft tissue augmentation should be done first, then CAF is done after three months from the first surgical procedure [9, 10].

3.1.1. Clinical outcomes (Table 1)

Using CAF + CTG or CAF + ADM in the management of Miller's class III/IV is mainly indicated when an adequate amount of keratinized gingiva is present. The percentage of root coverage for CAF + CTG ranges from 70-86% [8, 11, 12, 13, 14, 15, 16, 17], while it ranges from 60-63% for CAF + ADM [23], as it is summarized in Table 1.

The long-term stability of the treated class III/IV is significantly higher when EMD is added to CAF + CTG [18, 19, 20]. CTG provides a greater amount of keratinized tissue width (KTW) than ADM [25]. The addition of rhPDGF or EMD to ADM does not add any significant benefit [23, 26]. EMD is also considered as an alternative that could be used in combination with CAF and provides additional benefits [27, 28].

3.2. Free gingival graft (FGG)

Autogenous free gingival graft (FGG) characterized by high predictability to create an adequate band of keratinized mucosa and to stop the progression of gingival recession [31], relatively simple procedure, multiple teeth can be treated at the same time, easy tissue handling, but could present some disadvantages, such as postoperative discomfort and morbidity, two surgical sites (donor and receptor), risk of hemorrhage on the donor site, different color compared with adjacent tissues, and no

predictability of root coverage [32, 33, 34]. Thus, the indication of FGG is restricted to non-aesthetic areas [35].

The management of recession in the mandibular anterior area may face many challenges (such as high frenal attachment, thin gingival biotype, shallow vestibular depth, etc.). Therefore, FGG is highly indicated in this region [36].

3.2.1. Clinical outcomes (Table 2):

FGG provides an excellent amount of keratinized gingiva, especially when the amount of keratinized gingiva is inadequate. The amount of increase of keratinized gingiva ranges from 2-6 mm, with a fair percentage of root coverage ranging from 41-76% as shown in Table 2.

Many studies have shown that FGG and CTG provide similar outcomes when used to treat simple gingival recession [37]. However, no comparative studies were done on advanced recession cases.

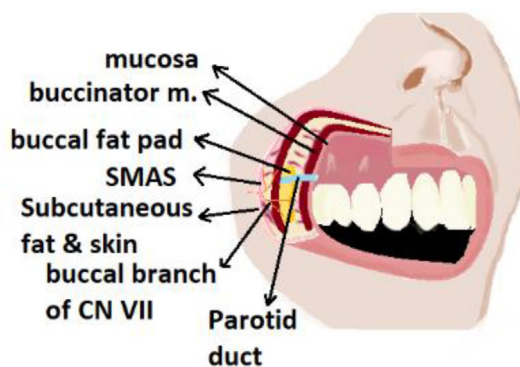


Figure 1. Anatomic relations of BFP. M. = muscle; N. = nerve; SMAS = subcutaneous musculoaponeurotic system.

Table 1. Clinical outcomes of CAF technique.

	Diagnosis	Sample size	Location of recession	Average amount of AG (mm)	WKG at the baseline (mm)	% Root coverage after 6 months	WKG change (mm) after 6 months
CAF + CTG [21]	Miller's class III	3	Maxillary anterior teeth	N/A	0.5	72%	2.3
CAF + CTG [29]	Miller's class III	15	Maxillary anterior teeth	2	2.6	85%	3.9
CAF + CTG [16]	Miller's class III	7	Mandibular anterior teeth	2	2.5	86.4%	3
CAF + CTG + EMD [30]	Miller's class III	12	Maxillary teeth (except molars)	2	3	70%	3.75
CAF + ADM [23]	Miller's class III	16	Maxillary & mandibular teeth (except molars)	2 mm	2.1	60.8%	2.1
CAF + ADM [24]	Miller's class III	8	Maxillary & mandibular teeth (except molars)	N/A	NA	62.5%	0.12–0.76

CAF: coronal advanced flap, CTG: Connective tissue graft, WKG: width of the keratinized gingiva.

Table 2. Clinical outcomes of FGG technique.

	Sample size	Diagnosis	Zone of recession	Amount of AG	Reduction in the gingival recession	Clinical attachment gain	% RC	Amount of increase in KG	(PPD After) – (PPD before)
Dias, et al. 2020 [40]	10	Miller's Class III & IV	Mandibular incisors	1.5 mm	3.4 mm after 12 months	3.1 mm after 12 months	76.4% after 12 months	6.1 mm After 3 months	N/A
Remya, et al. 2008 [41]	12	Miller's Class III	Mandibular incisors	1.2 mm	1.7 mm after 12 months	2.33 mm after 12 months	41.25% after 12 months	N/A	-0.42 mm after 12 months
Gul, et al. 2018 [42]	20	Miller's Class I & II & III	Mandibular incisors	1.75 mm	1.27 mm after 6 months	N/A	N/A	2.6 mm after 6 months	N/A
Yildırım, et al. 2015 [43]	1	Miller's Class III	Mandibular incisors	2 mm	2 mm after 8 months	2.5 mm after 8 months	50% after 8 months	4.5 mm after 8 months	-0.5 mm after 8 months
Miller, et al. 1985 [44]	21	Miller's Class III	Mandibular incisors	N/A	3 mm after 6 months	N/A	98.1% after 6 months	N/A	N/A

%RC: percentage of root coverage, KG: Keratinized gingiva, N/A: Not available, PPD: Pocket probing depth.

Table 3. Clinical outcomes of PBFP technique.

	Sample size	Diagnosis	Location of recession	Amount of AG	Reduction in the gingival recession	Clinical attachment gain	% MRC	Amount of increase in KG	(PPD After) – (PPD before)
Monika, et al. 2020 [46]	15	Miller's Class III & IV	Maxillary posterior teeth	N/A	2.73 mm	0.87 mm	46.78%	1–2 mm	-0.8 m
Deepa, et al. 2018 [47]	10	Miller's Class II & III	Maxillary posterior teeth	2.5 mm	5.70 mm	N/A	89.30%	N/A	1 mm
Panda, et al. 2016 [48]	1	Miller's Class III	Maxillary posterior teeth	N/A	N/A	6.00 mm	N/A	N/A	N/A
Agarwal et al. 2014 [49]	1	Miller's Class IV	Maxillary posterior teeth	N/A	4 mm	4.00 mm	44%	N/A	N/A
Ercan et al. 2016 [50]	2	Miller's Class III	Maxillary posterior teeth	3 mm	N/A	N/A	20–45%	1–4 mm	N/A

N/A: Not available, PPD: Periodontal pocket depth, RC: Root coverage, KG: Keratinized gingiva.

Table 4. Clinical outcomes of tunnel technique

	Diagnosis	Treatment	Sample size	Location of recession	Average amount of KT at the baseline	Average amount of KT after RC	%MRC	%CRC
Fernández-Jiménez et al. [53]	Miller's Class III	Modified tunnel technique + CTG	10	Maxillary + Mandibular teeth	2.63 mm	3.74 mm after 6 months	58.7% after 6 months	50% after 6 months
Yaman et al. [55]	Miller's Class III	Modified tunnel technique + CTG	9	Maxillary + Mandibular teeth	2.72 mm	3.65 mm after 12 months	78% after 12 months	50% after 12 months
Aroca et al. [56]	Miller's Class III	Modified tunnel technique + CTG +/- EMD	20	Maxillary + Mandibular teeth	N/A	N/A	82–83% after 12 months	40% after 12 months

%MRC: percentage of root coverage, %CRC: percentage of complete root coverage, CTG: connective tissue graft, EMD: enamel matrix derivative.

FGG has a lower mean of shrinkage than ADM (16% versus 71%, respectively) [38], therefore, FGG has lower recession depth compared to ADM, however, FGG has lower esthetic perception [39].

3.3. Pedicle buccal fat pad (PBFP)

BFP is a specialized capsulated fat tissue, located between the buccinator muscle medially and masseter muscle laterally (Figure 1). Unlike subcutaneous fat, BFP does not undergo lipid metabolism, so its volume remains relatively constant over time. BFP is highly vascularized tissue, with minimal risk for necrosis and infection, also it has a tendency to re-epithelialize, so it can give an excellent color match. Moreover, BFP contains stem cells that help in periodontal regeneration.

PBFP was first used by Egyedi in 1977 to close oroantral communication. It is characterized by ease of manipulation and stabilization, with minimal donor site morbidity.

In the last two decades, many periodontists tried to use PBFP in treating gingival recession, especially, severe cases in the maxillary posterior region, and it showed optimistic results (Table 4).

3.3.1. Clinical outcomes (Table 3)

PBFP graft technique provides optimistic results in treating of advanced gingival recession, especially in the maxillary posterior region, these results are summarized in Table 3.

PBFP has relatively same clinical outcomes as connective tissue graft, but has less discomfort than connective tissue graft [45].

3.4. Tunnel procedure combined with grafting material

Tunnel procedure for recession management was introduced by Allen AL in 1994, it was called the “supraperiosteal envelope technique” [51]. In 2011, Zadeh introduced the vestibular incision subperiosteal tunneling access technique (i.e., VISTA), which replaced the Allen technique, and became very popular [52]. Later on, in 2018, the VISTA

technique was modified into m-VISTA, which is characterized by ease of application, and reduced surgical time [53, 54].

3.4.1. Clinical outcomes (Table 4)

Tunnel technique showed complete root coverage in about 50% of advanced cases, with mean of root coverage ranged from 58% to 83% [53, 55, 56]. However, more randomized clinical trials with longer follow-ups are needed [57]. Neves et al. compared connective tissue graft when used with tunnel procedure or coronal advanced flap in a well-designed RCT, the results indicated that both treatment options provide the same outcomes when used to treat single gingival recession [58]. Gobbato et al (2016) found the same results, about 52–60% of patients achieved complete root for both treatment options (CAF + CTG or Tunnel + CTG). However, connective tissue graft with a coronal advanced flap was associated with less postoperative patient's discomfort, as well as, less chair time [59]. Tavelli et al. showed higher root coverage percentage for CAF as compared with tunnel procedure when the same graft is used [60]. Fahmy et al. compared CTG and ADM when are used with tunnel technique, there were no significant difference in the percentage of mean root coverage, this indicates that we can use any of them [61].

The addition of rhPDGF-BB to tunnel technique combined with CTG is significantly better than tunnel technique with CTG alone in treating advanced gingival recession in mandibular incisors [56, 62, 63].

4. Conclusion

In advanced gingival recession, coronally advanced flap with connective tissue graft provides best clinical outcomes, with percentage of root coverage reaches 86%. Free gingival graft is excellent choice when the amount of keratinized gingiva is inadequate. However, it does not provide a color match, thus it is not suitable in the esthetic zone. Pedicle buccal fat pad shows varying results, the percentage of root coverage ranges from 46–89%. However, it is limited to upper posterior region.

Tunnel technique is also an excellent technique to manage gingival recession, it provides comparable results as coronally advanced flap, but it is more sensitive technique.

Declarations

Author contribution statement

All authors listed have significantly contributed to the development and the writing of this article.

Funding statement

This research did not receive any specific grant from funding agencies in the public, commercial, or not-for-profit sectors.

Data availability statement

Data included in article/supp. material/referenced in article.

Declaration of interest's statement

The authors declare no conflict of interest.

Additional information

No additional information is available for this paper.

References

- M.M. Kassab, R.E. Cohen, The etiology and prevalence of gingival recession, *J. Am. Dent. Assoc.* 134 (2003).
- M.G. Marini, S.L.A. Greggi, E. Passanezi, A.C.P. Sant'Ana, Gingival recession: prevalence, extension and severity in adults, *J. Appl. Oral Sci.* 12 (2004) 250–255.
- S. Mythri, et al., Etiology and occurrence of gingival recession - an epidemiological study, *J. Indian Soc. Periodontol.* 19 (2015).
- G. Pini-Prato, The Miller classification of gingival recession: limits and drawbacks, *J. Clin. Periodontol.* 38 (2011).
- P.D. Miller, A classification of marginal tissue recession, *Int. J. Periodontics Restor. Dent.* 5 (1985).
- P.D. Miller, Miller classification of marginal tissue recession revisited after 35 years, *Comp. Cont. Educ. Dent.* 39 (2018).
- V. Moraschini, et al., Effectiveness of connective tissue graft substitutes for the treatment of gingival recessions compared with coronally advanced flap: a network meta-analysis, *Clin. Oral Invest.* 24 (2020) 3395–3406.
- A. Dai, J.P. Huang, P.H. Ding, L.L. Chen, Long-term stability of root coverage procedures for single gingival recessions: a systematic review and meta-analysis, *J. Clin. Periodontol.* 46 (2019).
- E.P. Allen, P.D. Miller, Coronal positioning of existing gingiva: short term results in the treatment of shallow marginal tissue recession, *J. Periodontol.* 60 (1989).
- P. Cortellini, G. Pini Prato, Coronally advanced flap and combination therapy for root coverage. Clinical strategies based on scientific evidence and clinical experience, *Periodontol.* 2000 59 (2012).
- F. Cairo, Periodontal plastic surgery of gingival recessions at single and multiple teeth, *Periodontol.* 2000 75 (2017) 296–316.
- P. Hofmänner, et al., Predictability of surgical techniques used for coverage of multiple adjacent gingival recessions—A systematic review, *Quintessence Int.* 43 (2012) 545–554.
- G.P.P. Prato, D. Franceschi, P. Cortellini, L. Chambrone, Long-term evaluation (20 years) of the outcomes of subepithelial connective tissue graft plus coronally advanced flap in the treatment of maxillary single recession-type defects, *J. Periodontol.* 89 (2018) 1290–1299.
- D.N. Tatakis, et al., Periodontal soft tissue root coverage procedures: a consensus report from the AAP regeneration workshop, *J. Periodontol.* 86 (2015) S52–S55.
- F. Cairo, U. Pagliaro, M. Neri, Treatment of gingival recession with coronally advanced flap procedures: a systematic review, *J. Clin. Periodontol.* 35 (2008) 136–162.
- J. Nart, et al., Subepithelial connective tissue graft in combination with a coronally advanced flap for the treatment of Miller Class II and III gingival recessions in mandibular incisors: a case series, *Int. J. Periodontics Restor. Dent.* 32 (2012).
- J.R. Wessel, D.N. Tatakis, Patient outcomes following subepithelial connective tissue graft and free gingival graft procedures, *J. Periodontol.* 79 (2008).
- F. Mercado, S. Hamlet, S. Ivanovski, Subepithelial connective tissue graft with or without enamel matrix derivative for the treatment of multiple class III/IV recessions in lower anterior teeth: a 3-year randomized clinical trial, *J. Periodontol.* 91 (2019) 473–483.
- F. Mercado, S. Hamlet, S. Ivanovski, Subepithelial connective tissue graft with or without enamel matrix derivative for the treatment of multiple Class III-IV recessions in lower anterior teeth: a 3-year randomized clinical trial, *J. Periodontol.* 91 (2020).
- G. Zucchelli, et al., The connective tissue graft wall technique and enamel matrix derivative to improve root coverage and clinical attachment levels in miller class IV gingival recession, *Int. J. Periodontics Restor. Dent.* 34 (2014) 601–609.
- J.B. César Neto, et al., Root coverage for single deep gingival recessions: outcomes based on a decision-making algorithm, *Int. J. Dent.* 2019 (2019) 17–19.
- C.M. Carney, et al., A comparative study of root defect coverage using an acellular dermal matrix with and without a recombinant human platelet-derived growth factor, *J. Periodontol.* 83 (2012).
- T.S. Barker, et al., A comparative study of root coverage using two different acellular dermal matrix products, *J. Periodontol.* 81 (2010).
- L. Chambrone, M.A. S Ortega, F. Sukekava, Root coverage procedures for treating single and multiple recession-type defects: an updated cochrane systematic review, *J. periodontol.* (2019).
- M.S. Shaikh, et al., Regenerative potential of enamel matrix protein derivative and acellular dermal matrix for gingival recession: a systematic review and meta-analysis, *Proteomes* 9 (2021) 1–14.
- N. Discepoli, R. Mirra, M. Ferrari, Efficacy of enamel derivatives to improve keratinized tissue as adjunct to coverage of gingival recessions: a systematic review and meta-analysis, *Materials (Basel)* 12 (2019) 1–22.
- M.A. Cueva, et al., A comparative study of coronally advanced flaps with and without the addition of enamel matrix derivative in the treatment of marginal tissue recession, *J. Periodontol.* 75 (2004).
- F. Cairo, et al., Coronally advanced flap with and without connective tissue graft for the treatment of single maxillary gingival recession with loss of inter-dental attachment. A randomized controlled clinical trial, *J. Clin. Periodontol.* 39 (2012).
- P.S.G. Henriques, A.A. Pelegrine, A.A. Nogueira, M.M. Borghi, Application of subepithelial connective tissue graft with or without enamel matrix derivative for root coverage: a split-mouth randomized study, *J. Oral Sci.* 52 (2010).
- U. Hangorsky, N.F. Bissada, Clinical assessment of free gingival graft effectiveness on the maintenance of periodontal health, *J. Periodontol.* 51 (1980).
- B. Kuru, S. Yıldırım, Treatment of localized gingival recessions using gingival unit grafts: a randomized controlled clinical trial, *J. Periodontol.* 84 (2013).
- D. da S. Feitosa, et al., Indicações atuais dos enxertos gengivais livres TT - current indications of free gingival grafts, *RGO* 56 (2008).
- R. Shah, R. Thomas, D. Mehta, Recent modifications of free gingival graft: a case series, *Contemp. Clin. Dent.* 6 (2015).
- O. Zuhr, D. Bäumer, M. Hürzeler, The addition of soft tissue replacement grafts in plastic periodontal and implant surgery: critical elements in design and execution, *J. Clin. Periodontol.* 41 (2014).
- I. Berlucchi, L. Francetti, M. Del Fabbro, M. Basso, R.L. Weinstein, The influence of anatomical features on the outcome of gingival recessions treated with coronally advanced flap and enamel matrix derivative: a 1-year prospective study, *J. Periodontol.* 76 (2005).
- S. Kayaalti-Yüksek, E. Yaprak, The comparison of the efficacy of gingival unit graft with connective tissue graft in recession defect coverage: a randomized split-mouth clinical trial, *Clin. Oral Invest.* (2021).
- P.-C. Wei, L. Laurell, M. Geivelis, M.W. Lingen, D. Maddalozzo, Acellular dermal matrix allografts to achieve increased attached gingiva. Part 1. A clinical study, *J. Periodontol.* 71 (2000).
- D.R.B. de Resende, et al., Acellular dermal matrix allograft versus free gingival graft: a histological evaluation and split-mouth randomized clinical trial, *Clin. Oral Invest.* 23 (2019) 539–550.
- J.J. Dias, M. Panwar, M. Kosala, Management of inadequate keratinized gingiva and millers class III or IV gingival recession using two-stage free gingival graft procedure, *J. Indian Soc. Periodontol.* 24 (2020).
- V. Remya, K. Kishore Kumar, S. Sudharsan, K. Arun, Free gingival graft in the treatment of class III gingival recession, *Indian J. Dent. Res.* 19 (2008).
- PR314, Assessment of creeping attachment after free gingival graft in treatment of isolated gingival recession, *J. Clin. Periodontol.* 45 (2018).
- S. Yıldırım, Gingival unit transfer using in the Miller III recession defect treatment, *World J. Clin. Cases* 3 (2015) 199.
- P.D. Miller, Root coverage using the free soft tissue autograft following citric acid application. III. A successful and predictable procedure in areas of deep-wide recession, *Int. J. Periodontics Restor. Dent.* 5 (1985).
- T.M. Deliberador, et al., Non-pedicle buccal fat pad grafts to treatment for class I and II gingival recessions: a clinical trial, *Braz. Dent. J.* 26 (2015) 572–579.
- K. Monika, et al., Evaluation of root coverage with pedicle buccal fat pad in class III and class IV gingival recession defects, *J. Fam. Med. Prim. Care* 9 (2020).
- D. Deepa, K.V.A. Kumar, Clinical evaluation of Class II and Class III gingival recession defects of maxillary posterior teeth treated with pedicle buccal fat pad: a pilot study, *Dent. Res. J.* 15 (2018) 11–16.
- S. Panda, M. Del Fabbro, A. Satpathy, A.C. Das, Pedicle buccal fat pad graft for root coverage in severe gingival recession defect, *J. Indian Soc. Periodontol.* 20 (2016).
- C. Agarwal, G.V. Gayathri, D.S. Mehta, An innovative technique for root coverage using pedicle buccal fat pad, *Contemp. Clin. Dent.* 5 (2014).
- E. Ercan, C. Candirli, C. Uysal, B.C. Uzun, E. Yenilmez, Treatment of severe gingival recession using pedicle buccal fat pad: histological and clinical findings, *Clin. Exp. Heal. Sci.* 6 (2016).
- A.L. Allen, Use of the supraperiosteal envelope in soft tissue grafting for root coverage. I. Rationale and technique, *Int. J. Periodontics Restor. Dent.* 14 (1994) 216–227.

- [52] H.H. Zadeh, Minimally invasive treatment of maxillary anterior gingival recession defects by vestibular incision subperiosteal tunnel access and platelet-derived growth factor BB, *Int. J. Periodontics Restor. Dent.* 31 (2011) 653–660.
- [53] A. Fernández-Jiménez, R. Estefanía-Fresco, A.M. García-De-La-Fuente, X. Marichalar-Mendia, L.A. Aguirre-Zorzano, Description of the modified vestibular incision subperiosteal tunnel access (m-VISTA) technique in the treatment of multiple Miller class III gingival recessions: a case series, *BMC Oral Health* 21 (2021) 1–11.
- [54] B. Najafi, P. Kheirieh, A. Torabi, E. Cappetta, Periodontal regenerative treatment of intrabony defects in the esthetic zone using modified vestibular incision subperiosteal tunnel access (M-VISTA), *Int. J. Periodontics Restor. Dent.* 38 (2018) e9–e16.
- [55] D. Yaman, K. Demirel, S. Aksu, C. Basegmez, Treatment of multiple adjacent miller class III gingival recessions with a modified tunnel technique: a case series, *Int. J. Periodontics Restor. Dent.* 35 (2015).
- [56] S. Aroca, A. Barbieri, M. Clementini, F. Renouard, M. de Sanctis, Treatment of class III multiple gingival recessions: prognostic factors for achieving a complete root coverage, *J. Clin. Periodontol.* 45 (2018) 861–868.
- [57] A. Fernández-Jiménez, et al., Complete root coverage in the treatment of Miller class III or RT2 gingival recessions: a systematic review and meta-analysis, *BMC Oral Health* 21 (2021).
- [58] F.L. Neves, et al., Randomized clinical trial evaluating single maxillary gingival recession treatment with connective tissue graft and tunnel or trapezoidal flap: 2-year follow-up, *J. Periodontol.* 91 (2020) 1018–1026.
- [59] L. Gobbato, et al., Patient morbidity and root coverage outcomes after the application of a subepithelial connective tissue graft in combination with a coronally advanced flap or via a tunneling technique: a randomized controlled clinical trial, *Clin. Oral Invest.* 20 (2016) 2191–2202.
- [60] L. Tavelli, et al., Efficacy of tunnel technique in the treatment of localized and multiple gingival recessions: a systematic review and meta-analysis, *J. Periodontol.* 89 (2018) 1075–1090.
- [61] R.A. Fahmy, M.R. Taalab, Modified tunnel technique for management of gingival recession in esthetic zone using acellular dermal matrix versus connective tissue graft, *Futur. Dent. J.* (2018).
- [62] S. Aroca, et al., Treatment of class III multiple gingival recessions: a randomized-clinical trial: clinical Innovation, *J. Clin. Periodontol.* 37 (2010) 88–97.
- [63] S. Parween, J. George, M. Prabhuji, Treatment of multiple mandibular gingival recession defects using MCAT technique and SCTG with and without rhPDGF-BB: a randomized controlled clinical trial, *Int. J. Periodontics Restor. Dent.* 40 (2020) e43–e51.